Coronary collaterals

Editor-In-Chief: C. Michael Gibson, M.S., M.D. [1] **Associate Editor(s)-in-Chief:** Vanessa Cherniauskas, M.D. [2]

Overview

Coronary collateral circulation confers a protective blood supply to the myocardium jeopardized by ischemia. During embryological development, an extensive overlay of inter coronary anastomoses derives from endothelial precursor cells which, in response to local signals, migrate and differentiate into new vessels in a process termed *vasculogenesis*. With progressive luminal encroachment of atheromatous plaque, collateral vasculature is remodeled to reduce overall resistance to the epicardial coronary flow which entails a decrease in the number of conduits and an increase in the caliber from 10–200 μm to 100–800 μm.[1] Following total or subtotal occlusion of an epicardial artery, *arteriogenesis* (recruitment of preexisting collateral channels) occurs conjointly with *angiogenesis* (sprouting of new vessels) to salvage the ischemic myocardium by shunting the blood from nonjeopardized territories. The mechanism responsible for modulating the processes of coronary vasculogenesis, arteriogenesis, and angiogenesis remains elusive. In the setting of myocardial infarction, the presence of well-developed collateralization is associated with a reduced infarct size,[2] mitigated QT prolongation,[3] lessened post-infarct ventricular dilatation,[4] and decreased mortality.[5] However, further prospective studies are warranted to determine whether therapeutic promotion of coronary collateral growth translates into favorable cardiovascular outcomes.

Criteria to Distinguish Between a Parent Epicardial Vessel and a Collateral Vessel

The criteria below is utilized to distinguish a collateral vessel from a segment of a parent epicardial artery.[6] If a vessel meets any of these criteria, it is considered a collateral vessel:

1. • If the vessel anastomoses with a distal segment of the same epicardial artery.
2. • If the vessel anastomoses with another vessel classified as a collateral.
3. • If the vessel has a mean diameter <0.7 mm.
4. • If the vessel (<0.7 mm) extends beyond one half of the distance between the epicardial artery segment that it originates from and any adjacent epicardial artery segment.
5. • If the vessel arises at a branch angle <135 degrees from the upstream vessel, thereby deviating from the normal range of epicardial branching angles.
6. • If the vessel has excessive tortuosity manifested by either a sine wave appearance or by a doubling back on itself.
7. • If the vessel has a corkscrew appearance.
8. • If the vessel is a branch arising from a major epicardial artery that was not apparent at both initial and follow-up time points.

Branches are not considered to be collaterals if any of the following criteria is met:

1. • The distal bifurcation of the left anterior descending artery (commonly referred to as the "moustache," "whale's tail," or "pitchfork") as long as each branch does not extend beyond 10 mm from the parent artery.
2. • Septal branches that do not extend more than half the distance to the inferior border of the heart.
3. • Diagonal branches that follow a conventional 30- to 45-degree branch pattern off the left anterior descending artery.
4. • Acute marginal branches in the right coronary artery may arise at an acute angle but are not considered collaterals if they are >0.7 mm unless they meet any of the aforementioned criteria.
5. • The sinoatrial and atrioventricular nodal branches of the right coronary artery are not considered collaterals unless they meet the aforementioned criteria for length or termination at an epicardial artery.

Collateral Frame Count

The collateral frame count is the number of cineframes required for contrast media to reach the recipient vessel. It is an index of coronary flow and is essentially a measure of the time for dye to travel down an epicardial artery to arrive at the recipient artery. The first frame is that frame in which dye extends across ≥70% of either the left main, the right coronary artery, a saphenous vein graft, or an internal mammary artery. The last frame counted is the frame in which dye first enters the recipient epicardial artery; complete opacification of the recipient artery is not required, only initial entry of dye into the recipient artery.[7]

Collateral Flow Grade

Gibson *et al.* devised the collateral flow grade system below to distinguish various degrees of flow in the collateral vessels:[8]

Grade 0 Flow

There is no flow in the collateral. This would be documented if a collateral had been visible at one time point but was not angiographically apparent at the other time point.

Grade 1 Flow

The collateral is barely apparent. Dye is not visible throughout the cardiac cycle but is present in at least 3 consecutive frames. There may not be clear antegrade dye motion in the collateral; it fills faintly and diffusely. There may be no clear connection with a major epicardial artery or side branch.

Grade 2 Flow

The collateral is moderately opaque but is present throughout at ≥75% of the cardiac cycle. There is antegrade motion of the dye rather than diffuse filling.

Grade 3 Flow

The collateral is well opacified and the column of dye is well defined (ie, >0.5 mm in diameter) but is <0.7 mm wide throughout the majority of its length. The collateral has clear antegrade dye motion.

Grade 4 Flow

The collateral is well opacified, fills antegrade, and is very large. It is >0.7 mm in diameter throughout its entire length.

Classification of the Collateral Circulation

Partial Collaterals

Partial collaterals are collaterals which fill branches of a major epicardial branch, but not the major artery itself. There is evidence of minimal to partial filling of the recipient branch epicardial arteries/infarct region. It is not necessary for one to see the branches connect directly to the major epicardial artery.

Complete Collaterals

Complete collaterals are well-developed collaterals which fill into a major epicardial branch, regardless of whether dye reaches the lesion which is collateralized or not. A subgroup of these collaterals are *bridging collaterals*, which arise from the culprit vessel and fill the major epicardial branch of the culprit vessel.

Myocardial Collaterals

Myocardial collaterals are collaterals which participate in the perfusion of the myocardium, but do not fill any visible arterial branch.

Rentrop Grade of Collateral Filling

Rentrop *et al.* proposed the system below to grade collateral filling of recipient arteries:[9]

Rentrop Grade 0

No visible filling of any collateral channels.

Rentrop Grade 1

Collateral filling of branches of the vessel to be dilated without any dye reaching the epicardial segment of that vessel (ie, RCA injection showing retrograde filling of septal branches to their origin from the LAD, without visualization of the latter occluded artery).

Rentrop Grade 2

Partial collateral filling of the epicardial segment of the vessel being dilated.

Rentrop Grade 3

Complete collateral filling of the vessel being dilated.

TIMI Grade of Collateral Filling

TIMI Study Group developed the system below to classify collateral networks to the infarct-related artery on a three-point scale as absent (grade 1), minimal (grade 2), or well-developed (grade 3), respectively:[10][11]

TIMI Grade 1 Collaterals

TIMI Grade 1 collaterals (absent collaterals) are defined as the absence of any collaterals to the occluded vessel supplying the area of infarction.

TIMI Grade 2 Collaterals

TIMI Grade 2 collaterals (minimal collaterals) are defined as collaterals resulting in faint opacification to a diameter not exceeding 1 mm in the occluded vessel or its branches, visualized distal to the obstruction in the occluded vessel supplying the area of the infarct.

TIMI Grade 3 Collaterals

TIMI grade 3 collaterals (well-developed collaterals) are defined as collaterals resulting in full opacification to a diameter greater than 1 mm in the occluded vessel or its branches, visualized distal to the obstruction in the occluded vessel that supplies the area of the infarction. A patient is considered to have collaterals to the infarct-related artery if the collateral perfusion grade is 2 or 3.

Recipient Filling Grade

Gibson *et al.* devised the grading scheme below which accounts for collaterals that appear to supply the myocardium directly without any apparent epicardial recipient:[12]

Recipient Grade 0

There are no angiographically apparent collaterals. This grade can only accompany a collateral flow grade of zero. It is designed specifically to account for cases in which there are collaterals present at one time point but not another.

Recipient Grade 1

Angiographically apparent collaterals extend into a region of myocardium with no angiographically apparent recipient vessel.

Recipient Grade 2

Minimal recipient filling by collaterals is manifested by minor side branch filling and no epicardial artery or epicardial side branch filling.

Recipient Grade 3

Moderate recipient filling by collaterals is manifested by complete filling of epicardial side branches and partial filling of a major epicardial artery (the left main, left anterior descending artery, circumflex, large obtuse marginal, the right coronary artery, or the PDA). The collateral filling of the epicardial artery may be obscured and washed out by competitive flow.

Recipient Grade 4

There is complete filling of a major epicardial segment.

Gallery

For more images, see Coronary collaterals case studies.

Images below depict collateral anastomoses between the RCA and the LAD.

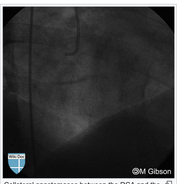

Collateral anastomoses between the RCA and the LAD

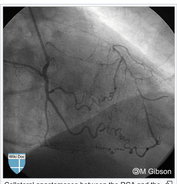

Collateral anastomoses between the RCA and the LAD. Collateral conduits are outlined in yellow.

References

1. • ↑ Fulton, W. F. (1963-11). "Arterial Anastomoses in the Coronary Circulation. I. Anatomical Features in Normal and Diseased Hearts Demonstrated by Stereoarteriography". *Scottish Medical Journal*. **8**: 420–434. ISSN 0036-9330. PMID 14075729.
2. • ↑ Habib, G. B. (1991-03). "Influence of coronary collateral vessels on myocardial infarct size in humans. Results of phase I thrombolysis in myocardial infarction (TIMI) trial. The TIMI Investigators". *Circulation*. **83** (3): 739–746. ISSN 0009-7322. PMID 1900223.
3. • ↑ Meier, Pascal (2010-05). "An indicator of sudden cardiac death during brief coronary occlusion: electrocardiogram QT time and the role of collaterals". *European Heart Journal*. **31** (10): 1197–1204. doi:10.1093/eurheartj/ehp576. ISSN 1522-9645. PMID 20038512.
4. • ↑ Kodama, K. (1996-04). "Collateral channels that develop after an acute myocardial infarction prevent subsequent left ventricular dilation". *Journal of the American College of Cardiology*. **27** (5): 1133–1139. doi:10.1016/0735-1097(95)00596-X. ISSN 0735-1097. PMID 8609332.
5. • ↑ Meier, Pascal (2012-03). "The impact of the coronary collateral circulation on mortality: a meta-analysis". *European Heart Journal*. **33** (5): 614–621. doi:10.1093/eurheartj/ehr308. ISSN 1522-9645. PMID 21969521.
6. • ↑ Gibson, C. M. (1999-01). "Angiographic methods to assess human coronary angiogenesis". *American Heart Journal*. **137** (1): 169–179. ISSN 0002-8703. PMID 9878950.
7. • ↑ Gibson, C. M. (1999-01). "Angiographic methods to assess human coronary angiogenesis". *American Heart Journal*. **137** (1): 169–179. ISSN 0002-8703. PMID 9878950.
8. • ↑ Gibson, C. M. (1999-01). "Angiographic methods to assess human coronary angiogenesis". *American Heart Journal*. **137** (1): 169–179. ISSN 0002-8703. PMID 9878950.
9. • ↑ Rentrop, K. P. (1985-03). "Changes in collateral channel filling immediately after controlled coronary artery occlusion by an angioplasty balloon in human subjects". *Journal of the American College of Cardiology*. **5** (3): 587–592. ISSN 0735-1097. PMID 3156171.
10. • ↑ Sheehan, F. H. (1987-04). "The effect of intravenous thrombolytic therapy on left ventricular function: a report on tissue-type plasminogen activator and streptokinase from the Thrombolysis in Myocardial Infarction (TIMI Phase I) trial". *Circulation*. **75** (4): 817–829. ISSN 0009-7322. PMID 3103950.
11. • ↑ Habib, G. B. (1991-03). "Influence of coronary collateral vessels on myocardial infarct size in humans. Results of phase I thrombolysis in myocardial infarction (TIMI) trial. The TIMI Investigators". *Circulation*. **83** (3): 739–746. ISSN 0009-7322. PMID 1900223.
12. • ↑ Gibson, C. M. (1999-01). "Angiographic methods to assess human coronary angiogenesis". *American Heart Journal*. **137** (1): 169–179. ISSN 0002-8703. PMID 9878950.

Coronary Angiography

Home

General Principles
Overview
Historical Perspective
Contraindications
Appropriate Use Criteria for Revascularization
Complications
Technique
Film Quality

Anatomy & Projection Angles

Normal Anatomy
Coronary arteries
Dominance
Right System
Left System
Left Main
Left Anterior Descending
Circumflex
Median Ramus

Anatomic Variants
Separate Ostia
Anomalous Origins
Case Example
Fistula

Projection Angles
Standard Views
Left Coronary Artery
Right Coronary Artery

Epicardial Flow & Myocardial Perfusion

Epicardial Flow
TIMI Frame Count
TIMI Flow Grade
TIMI Grade 0 Flow
TIMI Grade 1 Flow
TIMI Grade 2 Flow
TIMI Grade 3 Flow
TIMI Grade 4 Flow
Pulsatile Flow
Deceleration

Myocardial Perfusion
TIMI Myocardial Perfusion Grade
TMP Grade 0
TMP Grade 0.5
TMP Grade 1
TMP Grade 2
TMP Grade 3

Lesion Complexity

ACC/AHA Lesion-Specific Classification of the Primary Target Stenosis

Preprocedural Lesion Morphology
Eccentricity
Irregularity
Ulceration
Intimal Flap
Aneurysm
Sawtooth Pattern
Length
Ostial location
Angulation
Proximal tortuosity
Degenerated SVG
Calcification
Total occlusion
Coronary Artery Thrombus
TIMI Thrombus Grade
TIMI Thrombus Grade 0
TIMI Thrombus Grade 1
TIMI Thrombus Grade 2
TIMI Thrombus Grade 3
TIMI Thrombus Grade 4
TIMI Thrombus Grade 5
TIMI Thrombus Grade 6

Lesion Morphology
Quantitative Coronary Angiography
Definitions of Preprocedural Lesion Morphology
Irregular Lesion
Disease Extent
Arterial Foreshortening
Infarct Related Artery
Restenosis
Degenerated SVG
Collaterals
Aneurysm
Bifurcation
Trifurcation
Ulceration

Left ventriculography

Technique
Quantification of LV Function
Quantification of Mitral Regurgitation

• V • T • E

Coronary Angiography

Coronary Anatomy	Normal coronary anatomy • Anomalous origins of coronary arteries (Left coronary artery • Right coronary artery) • Congenital abnormalities of coronary arteries • Coronary artery segments • Cinefilm frame speed • Coronary artery dominance (Left dominance • Right dominance • Co-dominance)
TIMI Flow Grade	TIMI flow grade 0 • TIMI flow grade 1 • TIMI flow grade 2 • TIMI flow grade 3
TIMI Frame Count	TFC for SVG • TIMI Myocardial Frame Count • Washout TIMI Frame Count
TIMI Myocardial Perfusion Grade	TIMI MPG 0 • TIMI MPG 1 • TIMI MPG 2 • TIMI MPG 3
Thrombus Grading	Thrombus Grade 0 • Thrombus Grade 1 • Thrombus Grade 2 • Thrombus Grade 3 • Thrombus Grade 4 • Thrombus Grade 5 • Thrombus Grade 6
Lesion Complexity	Type A • Type B_1 • Type B_2 • Type C
Dissection Classification	Type A • Type B • Type C • Type D • Type E • Type F
Coronary Collaterals	Grade 0 • Grade 1 • Grade 2 • Grade 3 • Rentrop and Cohen's Collateral Classification
Lesion Morphology	Myocardial bridge •Definitions of Preprocedural Lesion Morphology • Luminal irregularities • Disease extent • Arterial foreshortening • Infarct related artery (Culprit lesion) • Reocclusion • Restenosis • Degenerated saphenous vein graft • Coronary artery fistula
Angiographic complications	Distal embolization • Coronary spasm • Abrupt closure • Side branch loss • Slow flow • No-reflow • Pulsatile flow • Flow deceleration • Ectasia • Intimal flap • Staining •
Performing Coronary Angiography	Patient preparation • Catheter selection • Standard angiographic views • High risk groups • Patients with special need • Access site closure (Manual compression • Assisted compression • Closure devices) •
Quantitative Coronary Angiography (QCA)	Minimal lumen diameter • Percent stenosis • Reference diameter • Lesion length • Residual stenosis • Average reference segment diameter • Plaque area • Plaque volume •
Contrast Media	High-osmolar contrast media • Iso-osmolar contrast media • Low-osmolar contrast media
Left Ventriculography & Aortography	Ejection fraction • Aortography • Quantitative Left Ventricular Analysis (LAO projection • RAO projection • LVA) • Left Ventricular Wall Motion Analysis (Normokinesia • Hypokinesia • Akinesia • Dyskinesia • Aneurysm) • Evaluation of mitral regurgitation • Evaluation of aortic regurgitation
Right Heart Catheterization	Pressure waveforms (Right atrial pressure • Riright ventricular pressure • Pulmonary artery pressure • Pulmonary artery wedge-pressure) • Endomyocardial biopsy
Complications	Access site complications • Dumping • Contrast hypersensitivity • Contrast induced nephropathy • Hypotension • Hypertension • Dissection • Vessel perforation • Acute myocardial infarction • Ventricular fibrillation • Cardiac arrest • Stroke • ASD • VSD • Pulmonary emboli • Myocardial rupture • Peripheral arterial emboli • Radiation injury

Categories: • CS1 errors: dates | • Pages with citations using unsupported parameters | • Cardiology | • Angiopedia

Navigation WikiDoc | WikiPatient | Up To Date Pages | Recently Edited Pages | Recently Added Pictures
Table of Contents In Alphabetical Order | By Individual Diseases | Signs and Symptoms | Physical Examination | Lab Tests | Drugs
Editor Tools Create a New Page | Become an Editor | Editors Help Menu | Upload a Picture or File | Maintain Pages | What Pages Link Here

There is no pharmaceutical or device industry support for this site and we need your viewer supported Donations | Editorial Board | Governance | Licensing | Disclaimers | Avoid Plagiarism | Policies

This page was last edited 05:33, 21 July 2014 by wikidoc user GeraldChi. Based on work by GeraldChi and wikidoc users Vanessa Cherni and Rim Halaby.

Content is available under Creative Commons Attribution/Share-Alike License unless otherwise noted; All rights reserved on Board Review content.

Privacy policy About wikidoc Disclaimers